

Submitted: 07/02/2017

Accepted: 16/06/2017

Published: 28/06/2017

Isolated limb perfusion electrochemotherapy for the treatment of an advanced squamous cell carcinoma of the hoof in a mare

Enrico Pierluigi Spugnini^{1,2,*}, Carlo Bolaffio², Licia Scacco² and Alfonso Baldi^{1,3}

¹Biopulse S.r.l., Naples, Italy

²Equivet Roma Hospital, Rome, Italy

³Department of Environmental, Biological and Pharmaceutical Sciences and Technologies Campania University "Luigi Vanvitelli", Caserta, Italy

Abstract

A twenty-year-old female saddle horse was referred for evaluation of a seven month, non-healing erosive lesion of the right hind hoof with proliferation and bleeding of the underlying soft tissues. This lesion had been twice surgically treated as a canker but rapidly recurred. Histological examination of the second excision revealed a well-differentiated squamous cell carcinoma. At presentation, the horse was mildly depressed, lame and partially non-weight-bearing on the right hind leg, which exhibited a 10 x 10 cm erosive and proliferative lesion remodeling the hoof. After completing staging procedures, the lesion was approached with surgery and intraoperative electrochemotherapy (ECT) administration of bleomycin in isolated limb perfusion. A second session of surgery and ECT was performed one month later, followed by three additional monthly sessions of ECT. During periodic recheck, the mare showed continuous improvement. One year after presentation, the mare was in complete remission and her gait markedly improved. ECT was well-tolerated and resulted in improved local control of a tumor in a challenging anatomical district.

Keywords: Bleomycin, Electrochemotherapy, Equine, Hoof, Squamous cell carcinoma.

Introduction

The equine hoof is site of multiple pathologies, generally of traumatic or inflammatory etiology such as septic navicular bursitis and navicular bone osteomyelitis, often extending to the distal interphalangeal joint and deep digital flexor tendon sheath or the underlying bones (Honnas *et al.*, 2003). Another common pathology is the infection of the medial or lateral collateral cartilage (commonly called quitter), often resulting in extensive necrosis and fistulation (Honnas *et al.*, 1988, 2003). Canker, another frequent finding, is a proliferative pododermatitis clinically appearing as chronic, hyperproliferative, suppurative, or pyogranulomatous dermatitis in the frog, bars, and sole, and (in advanced cases) the adjacent hoof wall (Moe *et al.*, 2010).

In contrast, tumors originating in the equine hoof wall or foot have been rarely described and are considered an uncommon cause of equine lameness (Berry *et al.*, 1991).

The hoof can be affected by benign proliferative lesions such as keratomas, a benign keratin-containing soft tissue mass that is localized between the hoof wall and the underlying distal phalanx (Lloyd *et al.*, 1988; Hamir *et al.*, 1992; Honnas *et al.*, 1994). Keratomas are usually composed of abundant keratin and squamous epithelial cells and occasionally associated with

granulation tissue and inflammatory cells (Lloyd *et al.*, 1988; Hamir *et al.*, 1992; Honnas *et al.*, 1994).

Malignant tumors are also scantily reported in the equine hoof, but include melanoma, squamous cell carcinoma, hemangioma and osteosarcoma (Barrett *et al.*, 1964; Christopher and Sastra, 1970; Kunze *et al.*, 1986; Honnas *et al.*, 1990; Berry *et al.*, 1991; Nelson and Baker 1998; Kleiter *et al.*, 2009).

Due to the generally advanced stage of the disease at first observation and the technical difficulty to obtain a complete excision, these tumors have a guarded prognosis and frequently require euthanasia of the patients. In this article, we report the successful treatment of a hoof carcinoma in a mare that was treated with surgery and isolated limb perfusion electrochemotherapy (ECT).

Case details

A 20-year-old female saddle horse with a history of chronic lameness in the right hind hoof was referred to our equine hospital. The mare had a seven month history of proliferation of the underlying soft tissues and bleeding of the right hind hoof, which had been debrided three months earlier upon the clinical hypothesis of a canker, but which had recurred shortly thereafter. Additionally, the mare had erosion of the hoof. At presentation the mare was quiet and depressed, but responsive to stimulation. The horse exhibited a

*Corresponding Author: Enrico Pierluigi Spugnini. Biopulse S.r.l., Naples, Italy.
Tel.: +39 3358428395. E-mail: info@enricospugnini.net

large ulcerative and proliferative lesion of the right hind hoof (Fig. 1A) and had a grade 4 lameness according to the American Association of Equine Practitioners (AAEP) lameness grading system (Table 1), evaluated through a dedicated veterinary software (EquineTec Pro Advanced Edition, EquineTec, Monroe, USA). The horse was staged with a complete blood cell count, biochemistry profile, and urinalysis. Additionally, an abdominal ultrasonographic exam and thoracic radiographs were performed. All hemato-biochemical parameters were within normal limits except for a relative neutrophilia (80% of the total white blood cells) with a neutrophil count of 7740 cell/ μ L, (range 5.4-14.3 $\times 10^3$), probably induced by the ulceration. The imaging exams were unremarkable. The proliferating tissue was biopsied and samples submitted for histopathological evaluation. The hoof wall mass revealed cellular invasion of the laminar corium, a high tumor cell mitotic index, and the formation of several keratin pearls; all features characteristics of well-differentiated squamous cell carcinoma (Fig. 2A). The therapeutic options for the patient were limited by the anatomical localization and the extension of the neoplastic disorder. Since amputation was not an option, it was decided on the basis of our group experience that the best approach would be a combination of surgical debulking and ECT (Spugnini et al., 2016a). The tumor site prevented a classical approach with intralesional chemotherapy due to the deep involvement of underlying structures, therefore it was decided to administer systemic bleomycin with localized ECT. The horse was sedated with a combination of acepromazine (Prequillan, Fatro, Ozzano Emilia, Italy), butorphanol (Nargesic, ACME, Cavriago, Italy) and romifidine (Sedivet, Boehringer Ingelheim, Milan, Italy) at the doses of 0.03 mg/kg, 0.04 mg/kg and 0,072 mg/kg respectively. Premedication was followed by diazepam (Valium, Roche, Milan, Italy) at the dose of 0.05 mg/kg and ketamine (Ketavet 100, MSD, Aprilia, Italy) at the dose of 2.2 mg/kg. At this point the patient was intubated and kept under general anesthesia with isoflurane (Forane, Abbott, Latina, Italy). Surgical debulking was performed, reaching the underlying digital cushion and coffin bone (Fig. 1B). At this point isolated limb perfusion, after application of a distal tourniquet, was performed. Thirty milligrams of Bleomycin (Bleomicina Solfato, Sanofi-Aventis, Milan, Italy) were diluted in 60 ml of NaCl 0.9% solution, and administered over 40 minutes, under ultrasonographic guidance (Fig. 1C, 1D). ECT was performed using a clinical electroporator (Onkodisruptor® Biopulse S.r.l., Naples, Italy) using needle array (double couple array for the center of the lesion, paired needles for the periphery), followed by booster with plate electrodes

(Patent application EP2221086A1) (Fig. 1E, 1F, 1G). The electrical parameters were as follows: 5 series of trains of 8 biphasic pulses at the voltage of 1000 V/cm, 1 Hz frequency, lasting 50 + 50 μ s with 300 μ s interpulse (total treatment time per cm 3.2 ms) were delivered to combine the joule effect of the needles with the tissue electroporation. The patient did not show any side effects due to the electroporation protocol and was discharged on antibiotics and NSAIDs: trimethoprim-sulfamethoxazole (Naxoprim, ACME S.r.l., Cavriago, Italy) 30 mg/kg OS SID and phenylbutazone (Bute ACME S.r.l., Cavriago, Italy) 2,2 mg/kg IV SID. The tumor showed a much slower recurrence compared to the first debulking. Additional sessions of surgery and ECT were performed twice at three week intervals, followed by two additional ECT sessions at three week intervals. A biopsy taken at the time of the third surgery showed histopathologic evidence of partial substitution of tumor tissue with fibrotic tissue and inflammatory reaction (Fig. 2B). After the fifth session of ECT there was necrosis of the connective tissues with secondary osteomyelitis (Fig. 2C), but no detectable tumor tissue. The horse was kept on antibiotics and NSAIDs as previously described and the hoof slowly healed over a period of three months after the last ECT session. A histopathology exam of bioptic tissue at three months showed complete remission of the tumor and its replacement by fibrovascular tissue (Fig. 2D). During this period, a special horseshoe was applied to prevent stress or mechanically induced fractures. The patient was still in remission after one year from the completion of the ECT protocol (Fig. 1H) and her gait greatly improved moving from a grade 4 to a grade 2 as measured by dedicated software (Huguet and Duberstein, 2012) (Table 1).

Table 1. American Association of Equine Practitioners (AAEP): lameness grading system.

Grade	Description
0	Lameness not perceptible under any circumstances.
1	Lameness is difficult to observe and is not consistently apparent, regardless of circumstances (e.g. under saddle, circling, inclines, hard surface, etc.).
2	Lameness is difficult to observe at a walk or when trotting in a straight line but consistently apparent under certain circumstances (e.g. weight-carrying, circling, inclines, hard surface, etc.).
3	Lameness is consistently observable at a trot under all circumstances.
4	Lameness is obvious at a walk.
5	Lameness produces minimal weight bearing in motion and/or at rest or a complete inability to move.

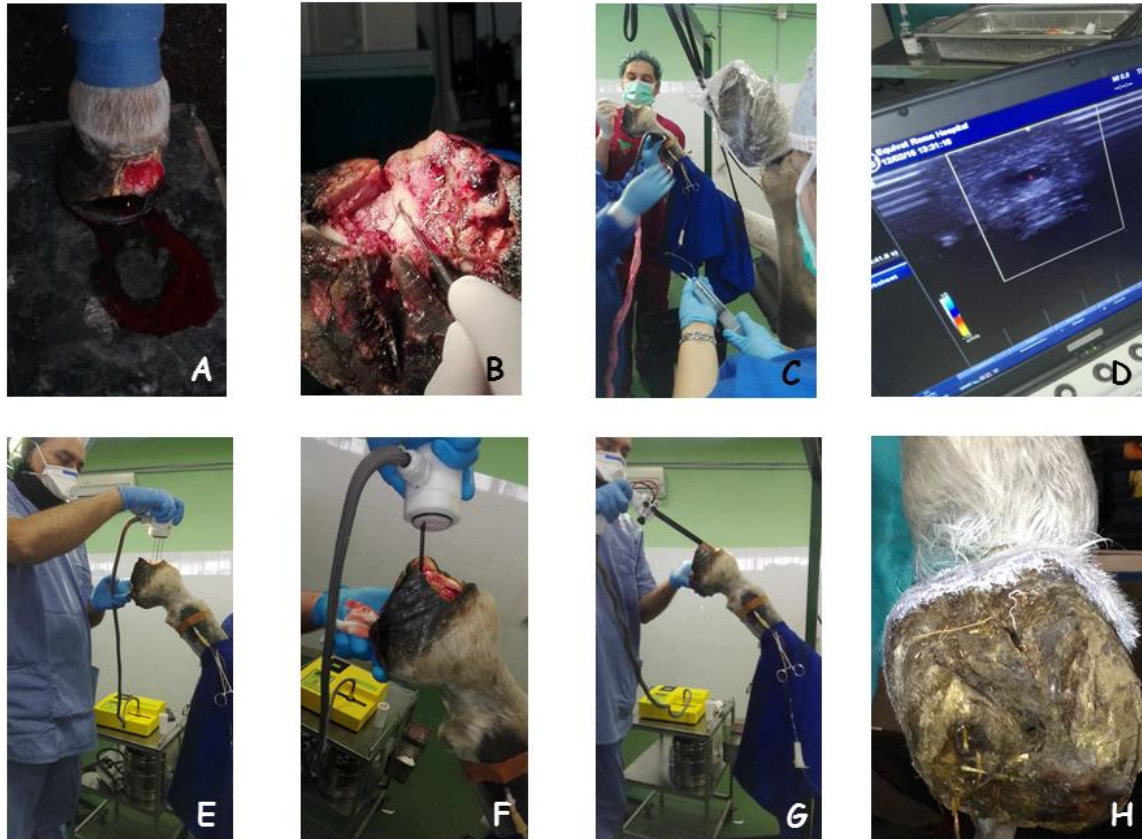


Fig. 1. (A): The tumor lesion at presentation. A large ulcerated neoplastic lesion affected the hoof of the horse hind leg. (B): Surgical debulking of the hoof neoplasm. (C, D): Ultrasound guided isolated limb perfusion chemotherapy. (E, F, G): Delivery of permeabilizing electric pulses by means of plate and different needle array electrodes (H): The patient 1 year after the last ECT session: there is no gross evidence of cancer disease in the hoof.

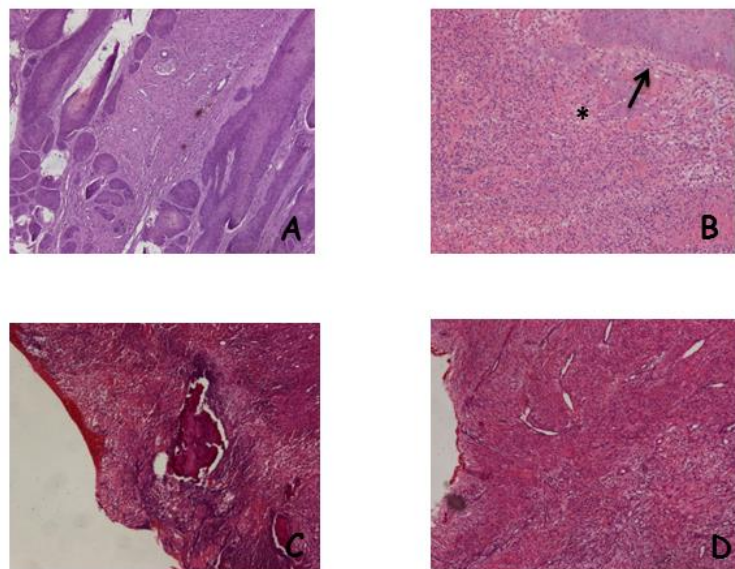


Fig. 2. (A): Histological appearance of the neoplasia at presentation: cellular invasion of the lamellar corium, a high tumor cell mitotic index, and the formation of several keratin pearls are visible (Hematoxylin and Eosin staining; original magnification X20). (B): Histopathology exam after the third ECT session showing partial tumor regression (arrow) and local inflammation and fibrosis (asterisk). (C): Histopathology exam after the fifth ECT session showing tumor regression and osteomyelitis. (D): Histopathology exam three months after the fifth ECT session showing complete tumor regression and its replacement by fibrovascular tissue.

Discussion

Squamous cell carcinoma of the equine hoof is rarely reported. According to the scant literature reports, the outcome is unfavorable due to the tumor location and clinical aggressiveness (Barrett *et al.*, 1964; Christopher and Sastra, 1970; Berry *et al.*, 1991). Several factors affected the therapeutic plan in this case: unusual tumor type and location, requirement for general anesthesia, unlikeliness of complete surgical excision, lack of information on radiation therapy feasibility and efficacy in this anatomical area, and unlikely efficacy of local and classical systemic chemotherapy in the anatomic region.

ECT is a loco-regional therapy that is becoming widely adopted in clinical oncology, especially for small animals, because of its greater local tumor control with minimal side effects (Spugnini *et al.*, 2016a, 2017). This technique couples the application of permeabilizing electric pulses on tumors or tumor beds in combination with the administration (either systemic or intralesional) of a chemotherapy drug (Spugnini *et al.*, 2014). It has been successfully employed to increase the chemotherapy efficacy in cats affected by squamous cell carcinoma (Spugnini *et al.*, 2015). Moreover, our group has been able to successfully treat malignant equine neoplasms (Spugnini *et al.*, 2011, 2016b; Scacco *et al.*, 2013). A major issue that needed to be addressed in neoplasms of the hoof was how to deliver the drug to the area, considering that the lack of soft tissue prevented intralesional chemotherapy. For this reason, we decided to resort to isolated distal limb perfusion using bleomycin for its reported higher efficacy against squamous cell carcinoma in other species and its much lower toxicity compared to cisplatin (Spugnini *et al.*, 2015, 2016a). In this case, the drug was delivered by adapting a currently used protocol for the delivery of antimicrobial to the distal part of the limb in horses (Rubio-Martinez and Cruz, 2006). The present protocol controlled the advanced neoplasm in our patient and was well-tolerated in terms of local and distal toxicoses. The observed osteomyelitis was probably induced by the aggressive surgical excision as well as by ECT, although the exact contribution of each component could not be assessed. Regardless, these side effects were successfully controlled by using systemic antibiotics and non-steroidal anti-inflammatory drugs. Sequential histopathology exams documented the complete regression of the tumor and the resolution of osteomyelitis with formation of fibrous tissue. From a functional point of view, the tumor breach was keratinized and the horse's gait greatly improved, going from a grade 4 lameness to a grade 2 accordingly to the AAEP lameness grading system. The horse was still in remission after one year from the histopathological evidence of tumor remission. In light of its high

efficacy and high tolerability with good cosmetic and functional results, ECT has been adopted at our hospital as the standard adjuvant therapy of incompletely excised solid tumors in horses.

Acknowledgements

Enrico P. Spugnini and Alfonso Baldi are stockholders of Biopulse S.r.l. The authors wish to thank Dr. Guy Beretich, PhD, for the critical and linguistic revision for this manuscript.

Conflict of interest

The authors declare that there is no conflict of interests.

References

- Barrett, R.B., Kenney, J.S. and Rickard, C.G. 1964. Epidermal laminar carcinoma of the hoof of a horse. *J. Am. Vet. Med. Assoc.* 144, 607-611.
- Berry, C.R., O'Brien, T.R. and Pool, R.R. 1991. Squamous cell carcinoma of the hoof wall in a stallion. *J. Am. Vet. Med. Assoc.* 199, 90-92.
- Christopher, K.J. and Sastry, G.A. 1970. Carcinoma of the hoof of a pony. *Indian Vet. J.* 47, 722-723.
- Hamir, A.N., Kunz, C. and Evans, L.H. 1992. Equine keratoma. *J. Vet. Diagn. Invest.* 4, 99-100.
- Honnas, C.M., Ragle, C.A. and Meagher, D.M. 1988. Necrosis of the collateral cartilage of the distal phalanx in horses: 16 cases (1970-1985). *J. Am. Vet. Med. Assoc.* 193, 1303-1307.
- Honnas, C.M., Liskey, C., Meagher, D.M., Brown, D. and Luck, E.E. 1990. Malignant melanoma in the foot of a horse. *J. Am. Vet. Med. Assoc.* 197, 756-758.
- Honnas, C.M., Peloso, J.G., Carter, G.K. and Moyer, W. 1994. Surgical management of coronary band avulsions and keratomas in horses. *Vet. Med.* 89, 984-988.
- Honnas, C.M., Dabareiner, R.M. and McCauley, B.H. 2003. Hoof wall surgery in the horse: approaches to and underlying disorders. *Vet. Clin. North Am. Equine Pract.* 19, 479-499.
- Huguet, E.E. and Duberstein, K.J. 2012. Effects of steel and aluminum shoes on forelimb kinematics in stock-type horses as measured at the Trot. *J. Equine Vet. Sci.* 32, 262-267.
- Kleiter, M., Velde, K., Hainisch, E., Auer, U. and Reifinger, M. 2009. Radiation therapy communication: equine hemangioma. *Vet. Radiol. Ultrasound* 50, 560-563.
- Kunze, K.J., Monticello, T.M., Jakob, T.P. and Crane, S. 1986. Malignant melanoma of the coronary band in a horse. *J. Am. Vet. Med. Assoc.* 188, 297-298.
- Lloyd, K.C., Peterson, P.R., Wheat, J.D., Ryan, A.E. and Clark, J.H. 1988. Keratomas in horses: seven cases (1975-1986). *J. Am. Vet. Med. Assoc.* 193, 967-970.
- Moe, K.K., Yano, T., Kuwano, A., Sasaki, S. and Misawa, N. 2010. Detection of tréponemes in

- canker lesions of horses by 16S rRNA clonal sequencing analysis. *J. Vet. Med. Sci.* 72, 235-239.
- Nelson, A.M. and Baker, D.C. 1998. Pedal osteosarcoma in a donkey. *Vet. Pathol.* 35, 407-409.
- Rubio-Martinez L.M. and Cruz, A.M. 2006. Antimicrobial regional limb perfusion in horses. *J. Am. Vet. Assoc.* 228, 706-712.
- Scacco, L., Bolaffio, C., Romano, A., Fanciulli, M., Baldi, A. and Spugnini, E.P. 2013. Adjuvant electrochemotherapy increases local control in a recurring equine anal melanoma. *J. Equine Vet. Sci.* 33, 637-639.
- Spugnini, E.P., D'Alterio, G.L., Dotsinsky, I., Mudrov, T., Dragonetti, E., Murace, G., Citro, G. and Baldi, A. 2011. Electrochemotherapy for the treatment of multiple melanomas in a horse. *J. Equine Vet. Sci.* 31, 430-433.
- Spugnini, E.P., Melillo, A., Quagliuolo, L., Boccellino, M., Vincenzi, B., Pasquali, P. and Baldi, A. 2014. Definition of novel electrochemotherapy parameters and validation of their in vitro and in vivo effectiveness. *J. Cell Physiol.* 229, 1177-1181.
- Spugnini, E.P., Pizzuto, M., Filipponi, M., Romani, L., Vincenzi, B., Menicagli, F., Lanza, A., De Girolamo, R., Lomonaco, R., Fanciulli, M., Spriano, G. and Baldi, A. 2015. Electroporation Enhances Bleomycin Efficacy in Cats with Periocular Carcinoma and Advanced Squamous Cell Carcinoma of the Head. *J. Vet. Intern. Med.* 29, 1368-1375.
- Spugnini, E.P., Azzarito, T., Fais, S., Fanciulli, M. and Baldi, A. 2016a. Electrochemotherapy as first line cancer treatment: experiences from veterinary medicine in developing novel protocols. *Curr. Cancer Drug Targets* 16, 43-52.
- Spugnini, E.P., Bolaffio, C., Scacco, L. and Baldi, A. 2016b. Electrochemotherapy increases local control after incomplete excision of a recurring penile fibrosarcoma in a stallion. *Open Vet. J.* 6, 234-237.
- Spugnini, E.P., Fais, S., Azzarito, T. and Baldi, A. 2017. Novel Instruments for the Implementation of Electrochemotherapy Protocols: From Bench Side to Veterinary Clinic. *J. Cell Physiol.* 232(3), 490-495.