

Submitted: 26/03/2016

Accepted: 29/07/2016

Published: 05/08/2016

## Cystolithiasis in a Syrian hamster: a different outcome

D. Petrini<sup>1</sup>, M. Di Giuseppe<sup>2,\*</sup>, G. Deli<sup>3</sup> and C. De Caro Carella<sup>4</sup>

<sup>1</sup>Freelance Veterinarian, Pisa, Italy

<sup>2</sup>Centro Veterinario per Animali Esotici, Viale Regione Siciliana Sud – Est 422-426, 90129 Palermo, Italy

<sup>3</sup>Freelance Veterinarian, Roma, Italy

<sup>4</sup>School of Veterinary Medicine, Louisiana State University, USA

### Abstract

A 14-month-old intact male Syrian hamster was admitted for lethargy and hematuria. A total body radiographic image and abdominal ultrasonography showed the presence of a vesical calculus. During cystotomy, a sterile urine sample was obtained and sent to the diagnostic laboratory along with the urolith for analysis. Urine culture was found negative for bacterial growth, and the urolith was identified as a calcium-oxalate stone. Diet supplementation with palmitoylethanolamide, glucosamine and hesperidin was adopted the day after discharge. One year follow up revealed no presence of vesical calculi. Although this is the report of a single clinical case, this outcome differs from the results reported in the literature characterized by recurrences after few months. Considering the positive outcome and the beneficial properties of palmitoylethanolamide, glucosamine, and hesperidin, these nutritional elements in Syrian hamsters, are recommended to reduce recurrence after surgical treatment of urolithiasis.

**Keywords:** Glucosamine, Hamster, Hesperidin, PEA, Urolithiasis.

### Introduction

Urolithiasis is a common disease in hamsters and it is associated with a high incidence of short-term recurrence after surgical treatment. The etiology of this pathology remains unknown, although dry food diet has been suggested as a possible predisposing factor. This case report describes diagnostic and surgical approaches, as well as dietary management, and successful long-term management of urolithiasis in a Syrian hamster.

### Case details

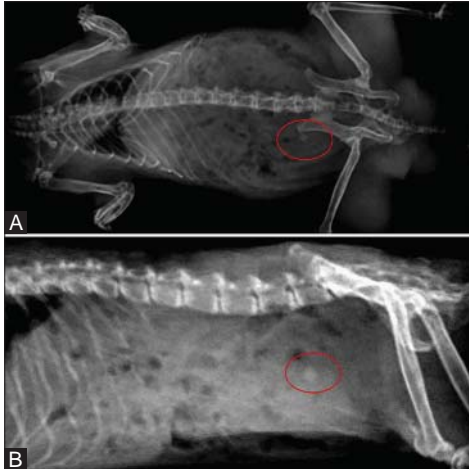A 14-month old intact male Syrian hamster was admitted for signs of lethargy and hematuria. The subject was housed in a 60x30 cm clear plastic cage lacking a cover. Specific recycled paper litter was used in the cage as substrate. Diet was constituted of a mix of several seeds, daily fresh greens, and fruits. Canine dry food in appropriate amounts was integrated once a week in order to increase protein intake. No sunflower seeds were included in the described diet.

During clinical examination, urine scald in the perineal area and weight loss were detected (-18.6% reduction of body weight since the last annual health check, occurred six months prior to presentation). Anesthesia of the subject was induced with isoflurane (Isoflo®, Esteve, Spain) (5%) in oxygen, delivered at 2 L/min into an induction chamber and maintained via face mask with isoflurane (2%) in oxygen (0.5 L/min) to allow diagnostic procedures. A ventro-dorsal and a latero-lateral radiographic projection showed the presence of a radio-opaque area in the caudal abdomen, compatible

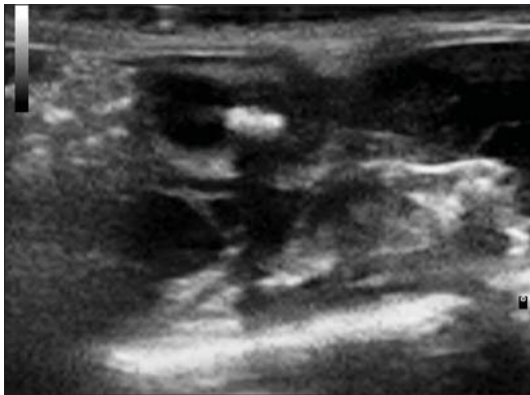
with the diagnosis of urolithiasis (Fig. 1). Abdominal ultrasonography showed an irregular, hyper-echoic urolith (3x3 mm) producing a black acoustic shadow inside the empty bladder (Fig. 2). Neither hydro-nephrosis nor hydro-ureter were detected during the study.

Since the size of the urolith would not allow its passage through the urethra, surgical removal via cystotomy was elected right away. The subject was sedated with midazolam (Midazolam®, Bioindustria L.I.M., Italy) 0.3 mg/kg, and buprenorphine (Buprenodale®, Dechra, Spain) 0.06 mg/kg. Anesthesia was induced and maintained with isoflurane (Isoflo®, Esteve, Spain) delivered in oxygen, via customized face mask. After aseptic preparation of the surgical site, laparotomy was approached via ventral midline using a #11 surgical blade. Once the bladder was exposed, it was isolated with gauze moistened with warm sterile saline (Fig. 3). Sterile cotton swabs were used to manipulate soft tissues during surgery to avoid damage with standardized surgical instruments. Incision of the bladder was made at the ventral aspect, close to the apex to avoid damage of the ureters. After removal of the stone, the bladder was irrigated with warm sterile saline and sutured using a single layer of continuous inverted suture pattern with a 6/0 poliglecaprone (Monocryl®, Ethicon, USA) as previously described<sup>1,2,3</sup>. Abdominal wall and skin were sutured with 4/0 poliglecaprone (Monocryl®, Ethicon, USA), using a continuous pattern suture. A sterile urine sample, as well as the urolith (Fig. 4), were submitted to a diagnostic laboratory for

\*Corresponding Author: Marco Di Giuseppe. Centro Veterinario per Animali Esotici, Viale Regione Siciliana Sud-Est 422-426, 90129 Palermo, Italy. Tel.: 0039 3481135412. E-mail: [marcodigiuseppe@yahoo.com](mailto:marcodigiuseppe@yahoo.com)

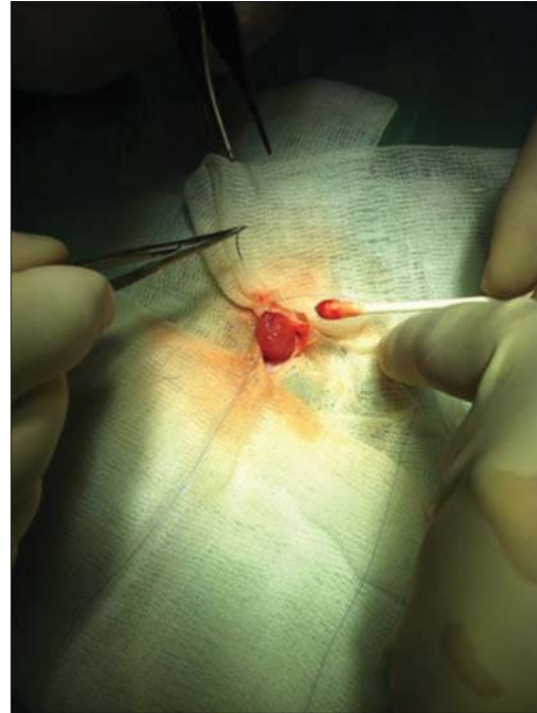


**Fig. 1.** Radiographic ventro-dorsal (A) and radiographic latero-lateral (B) projections of a 14 months old intact male Syrian hamster under general anesthesia showing a radio-opaque urolith (red circle).



**Fig. 2.** Abdominal ultrasonographic image showing the empty bladder with a 3x3 mm hyper-echoic urolith, producing a black acoustic shadow.

culture and sensitivity, and composition of the stone. The animal recovered uneventfully from anesthesia and surgery, and spontaneous urination began within a few minutes after complete recovery. On the same day, it was discharged with meloxicam (Metacam®, Boehringer Ingelheim, Germany) 0.2 mg/kg to be administered orally every twelve hours) and tramadol (Altadol®, Formevet, Italy) 5 mg/kg to be administered orally every twelve hours for five days for pain management, as well as with enrofloxacin (Baytril®, Bayer, Germany) 10 mg/kg to be administered orally every twenty-four hours. Lactated Ringer's solution was administered subcutaneously once per day at a dose of 57 ml/kg/day for five days. Urine culture was negative for bacterial growth, and urolith was identified as composed by calcium oxalate and ammonium. After proper informed consent was obtained from the owner, a diet supplement for canine and feline species



**Fig. 3.** Surgical view of the cystostomy. The Syrian hamster was positioned in dorsal recumbency, and the bladder was isolated with moistened gauzes.



**Fig. 4.** Particular of the urolith in relationship to a #11 surgical blade.

containing palmitoylethanolamide (PEA), glucosamine and hesperidin was added to the animal's regular diet. These three active ingredients are present in one single veterinary capsule, commercially available in Italy (Urys®, Innovet, Italy). The manufacturer's recommendation is to administer the liquid contained in one capsule for every ten kilograms of body weight for dogs and cats, and the indications for this product include preservation of the physiologic protective mechanisms of the urinary tract, protection from inflammation and oxidative damage, as well as preserving normal mucosal function. The content of one capsule was aspirated with a disposable 1 ml syringe, and one drop (about 0.025 ml) was given once a day orally to the animal, after the needle was removed from the syringe. The administered dose is equivalent

to 3.75 mg of PEA, 5 mg of glucosamine, and 3 mg of hesperidin per day equivalent approximately to 107 mg/kg of PEA, 143 mg/kg of glucosamine and 85.7 of hesperidin.

The animal was admitted to the hospital a year later for follow up. Physical examination and radiographic studies were repeated. No evidence of reoccurrence of urolithiasis was found, which was consistent with clinical signs and history of the past year.

#### Discussion

Available literature reports only two previous cases of cystoliths in hamster and in both cases recurrences were reported within a few months post-surgery (Bauck and Hagan, 1984; Lidderdale and St Pierre, 1990). To the authors' best knowledge, this is the only clinical case report with no recurrence was observed in a long-term follow up (Bauck and Hagan, 1984; Lidderdale and St Pierre, 1990; Johnson-Delaney, 1998; Capello, 2011a). In both cases reported in literature, the diagnosis was achieved by radiography showing a radiolucent cystolith and animals were both intact males showing hematuria, dysuria and incontinence (Bauck and Hagan, 1984; Lidderdale and St Pierre, 1990). Only in one of the two cases described the nature of the urolith was determined showing: magnesium, calcium and phosphate (Bauck and Hagan, 1984).

Normal urinary pH of rodents is basic therefore, uroliths composed by calcium and phosphate would be expected (Wagner and Mohebbi, 2010). For this reason in one case reported, acidification of urine with ammonium chloride administration was used to dissolve uroliths but no positive results were observed (Bauck and Hagan, 1984).

Although it is not demonstrated in hamster, interactions among dietary calcium, magnesium and phosphorus seem to affect the incidence, severity and type of uroliths in rats (Chow *et al.*, 1980).

The etiology of urolithiasis in Syrian hamsters is still unknown but dry food diet has been suggested as a possible predisposing factor (Capello, 2011b).

Palmitoylethanolamide is an endogenous fatty acid amide, exerting biological effects on chronic pain and inflammation, used to control hyper-reactivity of the urinary tract. Since its discovery, PEA has been considered to negatively modulate the inflammatory process. Its effects have been extensively investigated in vitro, in vivo, and in clinical studies. Notwithstanding some discrepancy, nowadays the efficacy of PEA in modulating mast cells, which may likely account for its anti-inflammatory, anti-angiogenic and analgesic properties, is well recognized (De Filippis *et al.*, 2013). In fact, it has been demonstrated that PEA significantly attenuates the degree of renal dysfunction, injury, and inflammation caused by ischemia-reperfusion injury in mice, that lowers arterial blood pressure, and can protect against hypertensive renal injury by increasing

the antioxidant defense and anti-inflammatory response (Di Paola *et al.*, 2012). It also has been shown that PEA can modulate the renin-angiotensin system in rats (Mattace Raso *et al.*, 2013). Glucosamine is an amino sugar and a prominent precursor in the synthesis of glycosylated proteins and lipids that plays an important role in the protection of the urothelium. Its efficacy in the treatment of feline idiopathic cystitis has been demonstrated (Farquhar-Smith and Rice, 2001; Panchaphanpong *et al.*, 2011). Furthermore, it has been shown to attenuate referred hyperalgesia in a dose-dependent fashion (Farquhar-Smith and Rice, 2001). The importance of glucosamine in this specific case is also supported by its presence in a specific nutritional support made for urinary tract health of hamsters (Natural Science Urinary Support Oxbow®). Unfortunately, the aforementioned product was not available on the Italian market when the reported clinical case was presented. The dose suggested by the manufacturer for one hamster is around 5 mg of glucosamine per day. The same dose of glucosamine was administered to the subject of this case report. Hesperidin is a flavanone glycoside found in citrus fruits that has chemopreventive effects. It effectively inhibits chemical carcinogenesis of the bladder in mice, and it has been suggested that such inhibition might be partly related to suppression of cell proliferation (Yang *et al.*, 1997).

Although this is the report of a single clinical case, this outcome differs from the results reported in the available literature. Considering the positive outcome, and the beneficial properties of dietary supplementation with palmitoylethanolamide, glucosamine and hesperidin, the authors encourage the use of these nutritional elements in Syrian hamsters to reduce recurrence after surgical treatment of urolithiasis.

#### References

- Bauck, L.A. and Hagan, R.J. 1984. Cystotomy for treatment of urolithiasis in a hamster. *J. Am. Vet. Med. Assoc.* 184, 99-100.
- Capello, V. 2011a. Common Surgical Procedures in Pet Rodents. *J. Exotic Pet Med.* 20, 294-307.
- Capello, V. 2011b. Pet hamster medicine and surgery, part III: infectious, parasitic and metabolic diseases. *Exotic DVM* 3, 27-32.
- Chow, F.H., Taton, G.F., Boulay, J.P., Lewis, L.D., Remmenga, E.E. and Hamar, D.W. 1980. Effect of dietary calcium, magnesium, and phosphorus on phosphate urolithiasis in rats. *Invest. Urol.* 17: 273-276.
- De Filippis, D., Negro, L., Vaia, M., Cinelli, M.P. and Iuvone, T. 2013. New insights in mast cell modulation by palmitoylethanolamide. *CNS Neurol. Disord. Drug Targets* 12, 78-83.
- Di Paola, R., Impellizzeri, D., Mondello, P., Velardi, E., Aloisi, C., Cappellani, A., Esposito, E. and

- Cuzzocrea, S. 2012. Palmitoylethanolamide reduces early renal dysfunction and injury caused by experimental ischemia and reperfusion in mice. *Shock*, 38, 356-366.
- Farquhar-Smith, P.W. and Rice, A.S.C. 2001. Administration of endocannabinoids prevents a referred hyperalgesia associated with inflammation of the urinary bladder. *Anesthesiology* 94, 507-513.
- Johnson-Delaney, C.J. 1998. Disease of the Urinary System of Commonly Kept Rodents: Diagnosis and Treatment. *Seminars Avian Exotic Pet Med.* 7, 81-88.
- Lidderdale, J.A. and St Pierre, S.J. 1990. Cystotomy for treatment of urolithiasis in a hamster. *Vet. Rec.* 127, 364.
- Mattace Raso, G., Simeoli, R., Russo, R., Santoro, A., Pirozzi, C., d'Emmanuele di Villa Bianca, R., Mitidieri, E., Paciello, O., Pagano, T.B., Orefice, N.S., Meli, R. and Calignano, A. 2013. N-Palmitoylethanolamide protects the kidney from hypertensive injury in spontaneously hypertensive rats via inhibition of oxidative stress. *Pharmacol. Res.* 76, 67-76.
- Panchaphanpong, J., Asawakarn, T. and Pusoonthornthum, R. 2011. Effects of oral administration of N-acetyl-D-glucosamine on plasma and urine concentrations of glycosaminoglycans in cats with idiopathic cystitis. *Am. J. Vet. Res.* 72, 843-850.
- Yang, M., Tanaka, T., Hirose, Y., Deguchi, T., Mori, H. and Kawada, Y. 1997. Chemopreventive effects of diosmin and hesperidin on N-butyl-N-(4-hydroxybutyl) nitrosamine-induced urinary-bladder carcinogenesis in male ICR mice. *Int. J. Cancer* 73, 719-724.