

Submitted: 19/01/2016

Accepted: 08/04/2016

Published: 15/04/2016

## A case of advanced second-degree atrioventricular block in a ferret secondary to lymphoma

F. Menicagli<sup>1</sup>, A. Lanza<sup>1</sup>, F. Sbrocca<sup>1</sup>, A. Baldi<sup>2</sup> and E.P. Spugnini<sup>3,\*</sup>

<sup>1</sup>Gianicolense Veterinary Centre, Via Lorenzo Valla 25/b, 00152 Rome, Italy

<sup>2</sup>Second University of Naples, Naples, Italy

<sup>3</sup>SAFU, Regina Elena Cancer Institute, Via delle Messi d'Oro 156, 00158 Rome, Italy

### Abstract

A female ferret was referred as an emergency for severe respiratory distress symptoms. At presentation, the patient was listlessness, dyspnoeic, and hyper-responsive. The clinical examination evidenced dyspnea with cyanosis, altered cardiac rhythm, and hepatomegaly. Electrocardiography showed an advanced second-degree atrioventricular (AV) block. The liver aspirate was diagnostic for lymphoma. The patient did not respond to supportive therapy and rapidly died. Post-mortem exams confirmed the presence of lymphoma with hepatic involvement. Moreover, a pericardial lymphocytic infiltration and a widespread myocardial nodular localization of lymphoma were evidenced as well. This condition was probably the cause of the cardiac arrhythmia. To the best of our knowledge, ours is the first report of cardiac lymphoma causing heart block in ferrets.

**Keywords:** Arrhythmia, Ferret, Isoproterenol, Lymphoma.

### Introduction

Acquired heart disease is common in ferrets over four years of age. A recent retrospective study showed that the most common echocardiographic abnormality in this species is valvular regurgitation (52%), often affecting the aortic and mitral valves (Lanieste *et al.*, 2014). Left ventricle hypertrophy was found in 15% of the study population, as well as dilated cardiomyopathy (4%) and restrictive cardiomyopathy (2%) (Malakoff *et al.*, 2012).

Moreover, the most commonly reported arrhythmias were sinus tachycardia or atrial fibrillation (often concomitant with atrial volume overload secondary to dilated cardiomyopathy) (Wagner, 2009).

First degree and second-degree atrioventricular (AV) block (1<sup>st</sup>-degree AV block, 2<sup>nd</sup>-degree AV block) have been frequently described while advanced 2<sup>nd</sup>-degree AV block or 3<sup>rd</sup>-degree AV block have been relatively uncommon (Wagner, 2009).

In ferrets arrhythmias are often associated with metabolic or systemic disorders. On the other hand, second and third-degree AV blocks caused by neoplastic pathologies affecting the heart muscle or appending structures have been seldom described (Wagner, 2009). In this article we report a case of severe AV block secondary to lymphoma with cardiac involvement that ultimately resulted in patient's death. The clinical and histological features of this uncommon pathology are described.

### Case Details

A nine-year-old female ferret was reported as an emergency at our center due to the sudden worsening

of respiratory symptoms, consisting of difficult breathing (cough, acute episodic dyspnea) and recurrent syncope-like episodes. At presentation the patient was listlessness, dyspnoeic, and hyper-responsive; weighing evidenced a 5% weight loss. Moreover, the ferret had a poor hair coat with evidence of thinning, located mainly nearby the tail and on the abdomen, and was moderately dehydrated. Auscultation revealed an increase in respiratory sounds, and decreased cardiac frequency. Heart rate was calculated to be around 60-65 beats per minute (bpm) while the literature reports a normal interval of 210-405 bpm (Dudás-Györki *et al.*, 2011). The diagnostic process included complete blood cell count (CBC), serum biochemistry profile, urinalysis, radiographic examination of the chest (three projections) and abdomen, with abdominal ultrasonography, and echocardiography exam. The haemochromocytometric examination revealed a slight eosinophilia while analysis of the blood smear showed lymphatic polymorphism and some atypical lymphocytes. The biochemical profile, on the other hand, showed only increases in alkaline phosphatase (93 UI/L; range: 25-60) and azotemia (79 mg/dl; range: 18-39), the latter associated with the concomitant increase in serum proteins, suggesting that this was due to the animal's state of dehydration. Serum electrophoresis showed hypergammaglobulinemia (1.6 g/dl; range: 0.31-0.81), and an altered albumine/globuline ratio (0.59; range: 1.05-1.33), suggestive of a persistent inflammatory condition (Quesenberry, 2012). Surface electrocardiographic examination was performed under sedation as elsewhere described (Church *et al.*, 2007). The anesthesiology protocol

\*Corresponding Author: Enrico P. Spugnini. SAFU, Regina Elena Cancer Institute, Via delle Messi d'Oro 156, 00158 Rome, Italy. E-mail: [info@enricospugnini.net](mailto:info@enricospugnini.net)

consisted of premedication with butorphanol (Dolorex, Intervet, Milan, Italy) at a dosage of 0.1 mg/kg IM, followed by induction and maintenance with isoflurane (Isoflo, Esteve, Maidenhead, UK).

The radiographic examination of the abdomen showed an increased liver size (not shown). The chest X-ray revealed an increase in the bronchial pattern and the presence of alveolar-type pulmonary edema (not shown). The abdominal ultrasonography revealed a widespread hepatomegaly with an infiltrative pattern (Fig. 1). A diffuse lymphadenomegaly was appreciated during the exam. The other organs, including the adrenal glands were within normal limits.

The echocardiographic examination revealed an alteration of the cardiac contractility, which was further evaluated with an electrocardiographic examination.

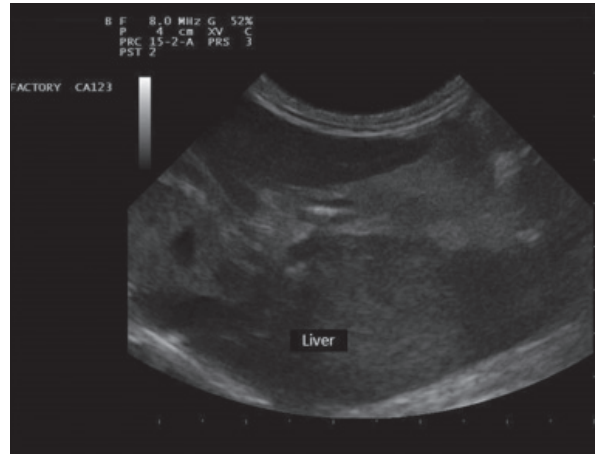
A marked bradycardia was detected (66 bpm), with the presence of non-conducted P waves in a ratio of 3:1. The exam also evidenced an increase in the duration of the QRS complexes (0.1 sec.) with morphology within the normal values, suggestive of an advanced 2<sup>nd</sup>-degree AV block (Wagner, 2009) (Fig. 2).

At this point, a tentative diagnosis of lymphoproliferative disease was formulated, with a concurrent diagnosis of cardiorespiratory impairment secondary to AV block.

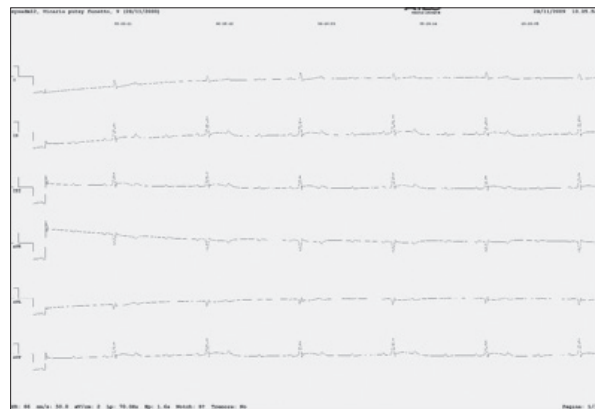
Enalapril (Nelio 2.5 mg tablets, Ati, Bologna, Italy) 0.5 mg/kg b.i.d. and furosemide (Diuren oral solution, Teknofarma, Turin, Italy) 0.5 mg/kg b.i.d. were orally administered together with oxygen therapy, to stabilize the patient. This procedure allowed performing an ultrasound guided fine needle aspirate of the liver that confirmed the diagnosis of lymphoma by cytology exam of the collected material. Cytology reported a large cell population made up by atypical lymphocytes accounting for approximately 85% of the sample and a residual 15% of prolymphocytes and lymphoblasts. Due to the patient's conditions, induction chemotherapy was deemed premature, and only prednisone was added to its therapy. The patient failed to respond to therapy and its conditions rapidly deteriorated ultimately leading to its death 36 hours after presentation. A necropsy was conducted showing a condition of congestion of the liver, kidneys, myocardial and pericardial tissue as well as the presence of a moderate amount of fluid in the pericardial space. Upon cytological examination, this exudate proved to be rich in lymphocytes and plasma cells. A subsequent histological examination confirmed the diagnosis of hepatic lymphoma (Fig. 3A). In the myocardium was evidenced a nodular lymphoid infiltrate as per cardiac localization of lymphoma. Furthermore, lymphocytic infiltrations were also found within the pericardium, as per non-specific pericarditis (Fig. 3B, C).

#### Discussion

First and 2<sup>nd</sup>-degree AV blocks represent the most common arrhythmias in the ferret while advanced



**Fig. 1.** B-mode ultrasonographic appearance of the hepatic lesion. A hyperechoic infiltrative pattern with a fine and homogenous structure is visible.

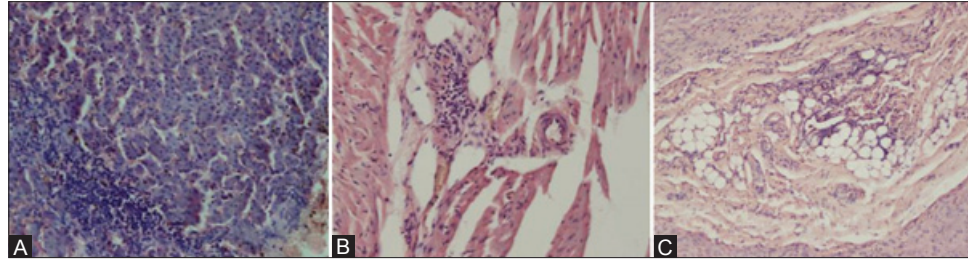


**Fig. 2.** Electrocardiogram showing the 2<sup>nd</sup>-degree heart block.

2<sup>nd</sup>-degree and 3<sup>rd</sup>-degree AV blocks are rare (Wagner, 2009; Church *et al.*, 2007).

The reported etiologies for these pathologies include inflammatory and degenerative lesions of the myocardial tissue and the mitral valve, with possible involvement of the conduction pathways, including the bundle of His (Kaneshige *et al.*, 2006, 2007a, 2007b).

To the best of our knowledge, this is the first case of AV block in ferrets secondary to a neoplastic condition, (cardiac lymphomatous infiltration). Noteworthy, despite the consistent hepatic involvement by the neoplasia (probably primary site of the disease), most of the clinical symptoms shown at presentation were ascribable to the cardiac spread of lymphoma cells. Interestingly, arrhythmias, and especially AV blocks associated with lymphomas have been so far reported only in human cardiology. This arrhythmia is often caused by ischemic and degenerative phenomena localized in the bundle of His (Vignola *et al.*, 1984). Similar histopathological aspects have also been described in dogs and in cats (Kaneshige *et al.*, 2006, 2007a, 2007b).



**Fig. 3.** (A) A nodular lymphoid infiltrate in the hepatic parenchyma (H&E, X20). (B) A nodular lymphoid infiltrate between the myocardial fibers (H&E, X20). (C) Lymphocytic infiltration in the connective tissue of the pericardium (H&E, X20).

The treatment of choice for advanced 2<sup>nd</sup>-degree and 3<sup>rd</sup>-degree AV block is the implantation of a pacemaker (Sanchez-Migallon Guzman *et al.*, 2006). However, the smaller size of ferrets makes this technique challenging. Current literature reports a few cases of implantation of monopolar epicardic pacemakers in animals affected by 3<sup>rd</sup>-degree AV block; unfortunately, the outcome of these implantations proved short-lived due to the associated complications (Sanchez-Migallon Guzman *et al.*, 2006). Alternatively, it has been proposed the medical management with isoproterenol (Wagner, 2006). Unfortunately, the rapid deterioration of the patient's conditions prevented us from attempting this approach. It is conceivable that AV block in our patient was secondary to its underlying neoplastic disease. To best of this knowledge, this condition has not been reported in ferrets so far. The management of a paraneoplastic condition always involves the control of the underlying tumor disease, however in our case, this proved to be unfeasible. Ferret owners should be aware of the high risk of development of neoplastic conditions in aged individuals and should promptly seek veterinary assistance in case atypical symptoms arise in their pets. Early diagnosis of lymphoma would allow a timely intervention and grant the highest chances of control of the tumor and the associated paraneoplastic syndrome(s).

#### References

- Church, W.M., Sisson, D.D., Oyama, M.A. and Zachary, J.F. 2007. Third degree atrioventricular block and sudden death secondary to acute myocarditis in a dog. *J. Vet. Cardiol.* 9, 53-57.
- Dudás-Györki, Z., Szabó, Z., Manczur, F. and Vörös, K. 2011. Echocardiographic and electrocardiographic examination of clinically healthy, conscious ferrets. *J. Small Anim. Pract.* 52, 18-25.
- Kaneshige, T., Machida, N., Itoh, H. and Yamane, Y. 2006. The anatomical basis of complete atrioventricular block in cats with hypertrophic cardiomyopathy. *J. Comp. Pathol.* 135, 25-31.
- Kaneshige, T., Machida, N., Nakao, S., Doiguchi, O., Katsuda, S. and Yamane, Y. 2007a. Complete atrioventricular block associated with lymphocytic myocarditis of the atrioventricular node in two young adult dogs. *J. Comp. Pathol.* 137, 146-150.
- Kaneshige, T., Machida, N., Yamamoto, S., Nakao, S. and Yamane, Y. 2007b. A histological study of the cardiac conduction system in canine cases of mitral valve endocardiosis with complete atrioventricular block. *J. Comp. Pathol.* 136, 120-126.
- Laniesz, D., Hébert, J., Larrat, S., Hélie, P., Pouleur-Larrat, B. and Belanger, M.C. 2014. Tetralogy of Fallot in a 6-year-old albino ferret (*Mustela putorius furo*). *Can. Vet. J.* 55, 456-461.
- Malakoff, R.L., Laste, N.J. and Orcutt, C.J. 2012. Echocardiographic and electrocardiographic findings in client-owned ferrets: 95 cases (1994-2009). *J. Am. Vet. Med. Assoc.* 241, 1484-1489.
- Quesenberry, K.E. 2012. Ferrets, Basic Approach to Veterinary care. In: Quesenberry KE, Carpenter JW, eds *Ferrets, Rabbits, and Rodents Clinical Medicine and Surgery*, 3<sup>rd</sup> Ed, St Louis: Elsevier Saunders, pp: 19-20.
- Sanchez-Migallon Guzman, D., Mayer, J., Melidone, R., McCarthy, R.J., McCobb, E., Kavirayani, A. and Rush, J.E. 2006. Pacemaker implantation in a ferret (*Mustela putorius furo*) with third-degree atrioventricular block. *Vet. Clin. North Am. Exot. Anim. Pract.* 9, 677-687.
- Vignola, P.A., Aonuma, K., Swaye, P.S., Rozanski, J.J., Blankstein, R.L., Benson, J., Gosselin, A.J. and Lister, J.W. 1984. Lymphocytic myocarditis presenting as unexplained ventricular arrhythmias: diagnosis with endomyocardial biopsy and response to immunosuppression. *J. Am. Coll. Cardiol.* 4, 812-819.
- Wagner, R.A. 2006. The Treatment of Third Degree Heart Block in Ferrets with Subcutaneous or Oral Isoproterenol. *Exotic DVM* 8, 6-7.
- Wagner, R.A. 2009. Ferret cardiology. *Vet. Clin. North Am. Exot. Anim. Pract.* 12, 115-134.