

Submitted: 14/08/2015

Accepted: 28/11/2015

Published: 25/12/2015

## Lymph node hemangioma in one-humped camel

M.A. Aljameel<sup>1,\*</sup> and M.O. Halima<sup>2</sup>

<sup>1</sup>Department of Pathology and Diagnosis, Nyala Veterinary Research Laboratory, Nyala, Sudan

<sup>2</sup>Department of Pathology and Diagnosis, Veterinary Research Institute, Khartoum, Sudan

### Abstract

Hemangioma is a benign tumor of blood and lymphatic vessels. It is common in skin, mucosa and soft tissues, and its occurrence in lymph nodes is extremely rare. A 10 year-old she-camel was slaughtered at Nyala slaughterhouse, South Darfur State, Sudan. Grossly, the carcass was emaciated. The left ventral superficial cervical lymph node was enlarged, hard on palpation and protruded outside the body. Its cut surface was dark red in color and measured (18 cm) in diameter. Histopathologically, the sections revealed vascular masses were composed of non-encapsulated clusters of small and medium sized with thick and thin-walled, filled with blood, separated by courageous stroma and surrounded by closely packed proliferating capillaries. To the best of our knowledge, this is the first record of the left ventral superficial cervical lymph node hemangioma in a camel in the Sudan.

**Keywords:** Hemangioma, Lymph node, One-humped camel, Sudan.

### Introduction

Hemangiomas are benign tumors of the blood and lymphatic vessels. In animals, hemangiomas are common in dogs but rare in cats, horses and other domestic animals (Goldschmidt and Hendrick, 2002). Although canine hemangiomas are commonly located in the skin (Hargis *et al.*, 1992; Schultheiss, 2004), they are also recorded in the spinal cord, tongue, liver, kidneys, spleen, conjunctiva and synovial joints (Cordy, 1979; Schoofs, 1997; Rallis *et al.*, 1998; Eddlestone *et al.*, 1999; Schultheiss, 2004; Pirie *et al.*, 2006; Miller *et al.*, 2007). Feline hemangiomas have been reported in the tongue, skin and conjunctiva (Crow *et al.*, 1981; Miller *et al.*, 1992; Pirie and Dubielzig, 2006). In the horse, cutaneous hemangiomas are the commonest (Johnson *et al.*, 1996).

Although hemangioma is common in skin, mucosa and soft tissues, its occurrence in lymph nodes is extremely rare (Reich *et al.*, 2000). Hemangioma has been recorded from abattoir derived liver specimens in camel (El-mahdy *et al.*, 2013).

Grossly, in the lymph node hemangioma the size of the involved lymph nodes ranges from 2 to 35 cm (Chan *et al.*, 1992; Dellacho *et al.*, 1999). Microscopically, hemangiomas are characterized by proliferating, vasoformative mesenchymal tissue forming capillary and cavernous vessels and less often, arterial and venous structures. Endothelial cells in these tumors may be surrounded by pericytes and fibroblasts (Calonje and Fletcher, 2007).

Hemangiomas may be classified as capillary or cavernous, lobular capillary, cellular and epithelioid (Chan *et al.*, 1992; Tsang *et al.*, 1994; Reich *et al.*, 2000). The capillary or cavernous hemangioma is more

often centered on the lymph node hilum or medulla with well-preserved nodal parenchyma (Tsang *et al.*, 1994; Ioachim and Medeiros, 2008) and is either a well-defined or poorly defined mass of closely packed capillaries or cavernous vessels lined by flat endothelial cells which can be empty or filled with blood (Dellacho *et al.*, 1999; Reich *et al.*, 2000). The lobular capillary type can almost replace the entire nodal parenchyma and has an appearance similar to a pyogenic granuloma (Chan *et al.*, 1992). The cellular type is composed of closely packed, nearly solid or rarely canalized, vascular channels that can be outlined by periodic acid-Schiff and reticulin stain (Chan *et al.*, 1992). The epithelioid type is characterized by plump endothelial cells (Chan *et al.*, 1992; Dellacho *et al.*, 1999). This report describes the gross and histopathological features of hemangioma present in the left ventral superficial cervical lymph node of a camel slaughtered at Nyala slaughterhouse in South Darfur State in Sudan.

### Case Details

A 10 year-old she-camel (*Camelus dromedarius*) was brought from West Darfur State and slaughtered at Nyala slaughterhouse for human consumption. Grossly, the carcass was emaciated. However, further examination did not reveal any detectable abnormalities. The size of the left ventral superficial cervical lymph node was enlarged, hard on palpation and protruded outside of the body surface (Fig. 1A). It was mounted 18 cm in diameter and dark red in color (Fig. 1B).

The lymph node was excised from the body and fixed in 10% neutral buffered formalin and submitted to the Department of Pathology in Veterinary Research Institute (VRI) in Khartoum for microscopic evaluation. The specimen was processed by routine methods,

\*Corresponding author: Mohammed Ahmed Aljameel, Nyala Veterinary Research Laboratory, P.O. Box 24, Nyala, South Darfur State, Sudan. Tel: +2499 12693622; Fax: +2497118 36110. Email: aljameel79@hotmail.com

embedded in paraffin wax, sectioned at 5µm thickness and stained with hematoxylin and eosin (H&E) for histopathological examination (Bancroft *et al.*, 1994). Histopathological findings revealed, vascular masses were composed of non-encapsulated clusters of small and medium sized with thick and thin-walled, filled with blood, separated by courageous stroma and surrounded by closely packed proliferating capillaries (Fig. 2). This finding is consistent with diagnosis of hemangioma (Dellacho *et al.*, 1999).

#### Discussion

Although hemangioma is common in the skin, mucosa and soft tissues, its occurrence in lymph nodes is extremely rare (Reich *et al.*, 2000). The gross and histopathologic features of the findings reported in the left ventral superficial cervical lymph node is consistent with the report of Dellacho *et al.* (1999) who described that grossly in the lymph node hemangioma, the size of the involved lymph nodes were ranged from 2 to 35 cm in diameter. Moreover, vascular masses, composed of non-encapsulated clusters of small and medium sized with thick and thin-walled, filled with blood, separated by courageous stroma and surrounded by closely packed proliferating capillaries were characteristic in this report. Previous reports have mentioned that capillary or cavernous hemangioma is more often centered on the lymph node hilum or medulla with well-preserved nodal parenchyma (Tsang *et al.*, 1994; Ioachim and

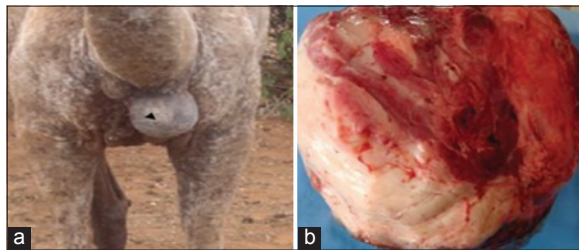
Medeiros, 2008) and is either a well-defined or poorly defined mass of closely packed capillaries or cavernous vessels lined by flat endothelial cells which can be empty or filled with blood (Dellacho *et al.*, 1999; Reich *et al.*, 2000). To the best of our knowledge, this is the first record of the left ventral superficial cervical lymph node hemangioma in a camel in the Sudan.

#### Acknowledgments

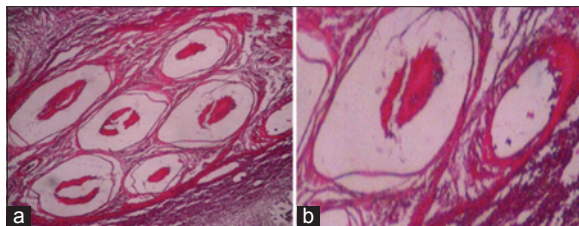
The authors would like to thank the staff members of the Department of pathology at Veterinary Research Institute for their technical assistance. Thanks are also due to the Director of Veterinary Research Institute and Animal Resources Research Corporation for his permission to publish this article.

#### References

- Bancroft, D.J., Cook, C.H., Striling, R.W. and Turner, D.R. 1994. Manual of histological techniques and their diagnostic application. Edinburgh, UK, Churchill Livingstone, pp: 15-118.
- Calonje, E. and Fletcher, C.D.M. 2007. Vascular tumors. In: Diagnostic Histopathology of Tumors, 3rd Edit. C. D. M. Fletcher, Ed, Churchill Livingstone, New York, pp: 41-81.
- Chan, J.K., Frizzera, G., Fletcher, C.D. and Rosai, J. 1992. Primary vascular tumors of lymph nodes other than Kaposi's sarcoma: analysis 39 cases and delineation of two new entities. *Am. J. Surg. Pathol.* 16(4), 335-350.
- Cordy, D.R. 1979. Vascular malformation and hemangiomas of the canine spinal cord. *Vet. Pathol.* 16, 275-282.
- Crow, S.E., Puley, L.T. and Wittenbrock, T.P. 1981. Lingual hemangioma in a cat. *J. Am. Anim. Hospital Assoc.* 17, 71-74.
- Dellacho, A., Fulcheri, E. and Campisi, C. 1999. A lymph nodal capillary-cavernous hemangioma. *Lymphology* 32(3), 123-125.
- Eddlestone, S., Taboada, J., Senior, D. and Paulsen, D.B. 1999. Renal haemangioma in a dog. *J. Small. Anim. Pract.* 40(3), 132-135.
- El-mahdy, M.M., Bakeer, A.M. and Wazzan, A.A. 2013. Pathological studies on liver affections in Saudi Arabia camels. *Egypt. J. Comp. Pathol. Clinic. Pathol.* 26, 85-108.
- Goldschmidt, M.H. and Hendrick, M.J. 2002. Tumors of the skin and soft tissues. In: Tumors in Domestic Animals, 4th Edit. D. J. Meuten, Ed., Iowa State Press, Ames, Iowa. pp: 45-117.
- Hargis, A.M., Ihrke, P.J., Spangler, W.L. and Stannard, A.A. 1992. Retrospective Clinicopathologic Study of 212 Dogs with Cutaneous Hemangiomas and Hemangiosarcomas. *Vet. Pathol.* 29, 316-328.
- Ioachim, H.L. and Medeiros, L.J. 2008. Hemangioma/hemangioendotheliomas In: Ioachim HL,



**Fig. 1.** Gross appearance of the left ventral superficial cervical lymph node showing enlargement, hard on palpation and protruded outside the body (a), dark red in color and measured (18 cm) in diameter (b).



**Fig. 2.** Histopathological sections of the left ventral superficial cervical hemangioma showing vascular masses were composed of non-encapsulated clusters of small and medium sized with thick and thin-walled, filled with blood, separated by courageous stroma and surrounded by closely packed proliferating capillaries (H&E x 40).

- Medeiros LJ eds. *Joachim's Lymph Node Pathology*. 4th ed. Philadelphia, PA: JB Lippincott, pp: 578-587.
- Johnson, G.C., Miller, M.A., Floss, J.L. and Turk, J.R. 1996. Histologic and immunohistochemical characterization of hemangiomas in the skin of seven young horses. *Vet. Pathol.* 33, 142-149.
- Miller, M.A., Pool, R.R. and Coolman, B.R. 2007. Synovial hemangioma in the stifle joint of a dog. *Vet. Pathol.* 44, 240-243.
- Miller, M.A., Ramos, J.A. and Kreeger, J.M. 1992. Cutaneous vascular neoplasia in 15 cats: clinical, morphological and immunohistochemical studies. *Vet. Pathol.* 29, 329-336.
- Pirie, C.G. and Dubielzig, R.R. 2006. Feline conjunctival hemangioma and hemangiosarcoma. A retrospective evaluation of 8 cases. *Vet. Ophthalmol.* 9, 227-231.
- Pirie, C.G., Knolinger, A.M., Thomas, C.B. and Dubielzig, R. 2006. Canine conjunctival hemangioma and hemangiosarcoma: a retrospective evaluation of 108 cases (1989-2004). *Vet. Ophthalmol.* 9, 215-226.
- Rallis, T.S., Tontis, D., Adamama-Moraitou, K.K., Mylonakis, M.E. and Papazoglou, L. 1998. Hepatic hemangioma associated with ascites in a dog. *Vet. Rec.* 142, 700-701.
- Reich, R.F., Moss, S. and Freedman, P.D. 2000. Intranodal hemangioma of the oral soft tissues: a case report of a rare entity with review of the literature. *Oral. Surg. Oral. Med. Oral. Pathol. Oral. Radiol. Endod.* 90(1), 71-73.
- Schoofs, S.H. 1997. Lingual hemangioma in a puppy: a case report and literature review. *J. Am. Anim. Hospital Assoc.* 33, 161-165.
- Schultheiss, P.C. 2004. A retrospective study of visceral and non-visceral hemangiosarcoma and hemangiomas in domestic animals. *J. Vet. Diag. Invest.* 16, 522-526.
- Tsang, W.Y., Chan, J.K., Dorfman, R.F. and Rosai, J. 1994. Vasoproliferative lesions of the lymph node. *Pathol. Annu.* 29(1), 748-749.