

Submitted: 18/01/2015

Accepted: 08/04/2015

Published: 07/05/2015

Metastatic anal sac carcinoma with hypercalcaemia and associated hypertrophic osteopathy in a dog

A. Giuliano*, R. Salgüero and J. Dobson

Queen's Veterinary School Hospital, University of Cambridge, Madingley Road, Cambridge, CB3 0ES, United Kingdom

Abstract

A seven-year-old male neutered Irish setter was treated for a metastatic anal sac adenocarcinoma (ASAC) and hypercalcaemia by complete surgical excision of the primary tumour and partial excision of the sublumbar lymph nodes. Further enlargement of the sublumbar lymph nodes was linked to recurrent hypercalcaemia 3 months after surgical treatment. Medical treatment with Toceranib and Clodronate showed modest results in the treatment of the tumour and the hypercalcaemia. Radiotherapy of the sublumbar lymph nodes and later concurrent carboplatin chemotherapy resulted in partial tumour remission with marked reduction in size of the lymph nodes and normalization of the calcaemia. Unfortunately, concurrently with subsequent relapse of the hypercalcaemia, the dog developed hypertrophic osteopathy (HO) and lumbar spinal metastasis and the dog was euthanized. To the authors' knowledge, this is the second case of metastatic apocrine gland carcinoma of the anal sac associated with HO and the first case that describe the development of HO late in the stage of the disease.

Keywords: Anal sac carcinoma, Hypercalcaemia, Hypertrophic osteopathy.

Introduction

Anal sac carcinoma is a relatively uncommon neoplasia in dogs that originates from the apocrine glands of the anal sac (Withrow, 2001). Anal sac carcinoma is an aggressive tumour with a tendency to metastasise to sublumbar lymph node and later to liver and lungs. Paraneoplastic hypercalcaemia is relatively common occurring in 25-53% of cases, often complicating the clinical management of the affected patients (Ross *et al.*, 1991; Bennett *et al.*, 2002; Williams *et al.*, 2003).

Hypertrophic osteopathy (HO) is characterized by the deposition of periosteal new bone mainly in the distal appendicular skeleton. In people, HO is mainly associated with pulmonary diseases, usually cancer (Carroll and Doyle, 1974). In dogs, HO has been described in both neoplastic and non-neoplastic conditions affecting mainly the thoracic cavity. However it has also been described in association with tumours of the bladder, liver esophagus and non-neoplastic conditions (Mather and Low, 1953; Brodey, 1971; Halliwell and Ackerman, 1974; Hesselink and van den Tweel, 1990; Wylie *et al.*, 1993; Watrous and Blumenfeld, 2002; Makungu *et al.*, 2007; Lee *et al.*, 2012; Salyusarenko *et al.*, 2013; Withers *et al.*, 2013). In a recent review of HO in dogs it was found that all the patients had pulmonary nodules in the lungs, two were primary pulmonary tumours and 28 were metastasis. The most common histological type of metastatic tumour was osteosarcoma, but other tumour types were present in particular; bladder transitional cell

carcinoma, prostatic carcinoma, renal carcinoma, renal adenocarcinoma with osteosarcomatous differentiation, chondrosarcoma, fibrosarcoma and leiomyosarcoma (Withers *et al.*, 2013).

The pathogenesis of HO is not completely understood; but was thought to be an increase in the peripheral vascular supply to the periosteum due to stimulation of nerve fibers that innervate vascular tissue directly related to the pharyngeal and vagus nerves (Carroll and Doyle, 1974). More recently, it has been proposed that the release of vascular endothelial growth factor (VEGF) and platelet-derived growth factor (PDGF) from platelets, due to abnormal platelet circulation could be involved in HO (Dickinson and Martin, 1987; Martinez-Lavin, 2007).

Case Details

A seven-year-old male neutered Irish setter was presented for severe polyuria and polydipsia and the suspicion of an anal sac tumour on the left side. Physical examination revealed a mass in the left anal gland. Haematology was unremarkable and biochemistry revealed moderate increase in total calcium, 3.94 mmol/L (ref range 2.15-2.72). The rest of the biochemistry was unremarkable.

Thoracic radiographs were performed which revealed two small pulmonary nodules (1 and 0.66 cm in size) that were suspicious of metastatic spread. Abdominal radiographs showed a marked sublumbar soft tissue opacity. Abdominal ultrasound revealed marked left sublumbar (most likely medial iliac) lymphadenopathy. Haematology was unremarkable and biochemistry

*Corresponding Author: Antonio Giuliano. Queen's Veterinary School Hospital, University of Cambridge, Madingley Road, Cambridge, CB3 0ES, United Kingdom. Email: ag847@cam.ac.uk

showed severe hypercalcaemia with an ionised calcium of 2.08 mmol/L (reference range, 1.18-1.4) with no other significant abnormalities detected. Fine needle aspirate of the left anal sac mass was not performed in view of the very typical presentation for an anal sac tumour. After saline (0.9%) fluid therapy at four times maintenance rate, oral clodronate 400 mg and a single subcutaneous injection of 6 mg dexamethasone, the hypercalcaemia almost resolved, (ionized calcium=1.48mmol/L) and surgery was performed. The left anal sac mass and ipsilateral medial iliac lymph node were removed resulting in post-operative normocalcaemia. Histopathology of the mass confirmed anal sac carcinoma with metastatic spread to the lymph node. The decision was made to monitor the patient and re-examine in the following three months. In the meantime, total calcium levels were checked monthly by the referring veterinary surgeon.

Three months after surgery, the dog presented with polyuria and polydipsia. An abdominal ultrasound confirmed the recurrence of metastatic carcinoma with marked sublumbar lymphadenopathy. Ionised calcium was elevated again. Treatment with toceranib 2.5 mg/kg every other day and clodronate 11 mg/kg twice a day was initiated. The dog achieved partial remission with reduction in size of the sublumbar lymph nodes and normocalcaemia. Toceranib was well tolerated with only mild neutropenia as side effect, which was controlled by reducing the dose of toceranib to every third day.

Unfortunately, the patient developed hypercalcaemia again after two months and thoracic and abdominal radiographs showed marked enlargement of the sublumbar lymph nodes. The two pulmonary nodules that were seen in previous examination were similar in size (Fig. 1a). Abdominal ultrasound revealed marked enlargement of the sublumbar lymph nodes, the rest of the abdomen was unremarkable and the dog had no other lymphadenopathy to suggest an alternative diagnosis of lymphoma. After discussion with the owner the decision was made to irradiate the sublumbar lymph nodes as a palliative treatment in the attempt to reduce hypercalcaemia and to restore a good quality of life. Two coarse fractions of 800 centigrays (cGys) radiation were administered 7 days apart via a parallel opposed beam configuration (400 cGys from right and left portals). Clodronate treatment was continued and toceranib was stopped. The radiotherapy resulted in reduction in size of the sublumbar lymph nodes and normocalcaemia. Hypercalcaemia was noticed again one month later in combination with further enlargement of the sublumbar lymph nodes. Another two fractions of radiotherapy were administered in combination with carboplatin 300 mg/m² every three weeks. The chemo- and radiotherapy resulted again in reduction in size of the sublumbar lymph nodes and

restoration of normocalcaemia without clodronate treatment.

Two months later, the patient again developed hypercalcaemia with severe increase in size of the sublumbar lymph nodes. On physical examination, the dog was lame in all four limbs and reluctant to stand up. All four distal limbs were swollen and painful on palpation. Thoracic and abdominal radiographs, abdominal ultrasound and radiographs of the appendicular long bones were performed. Previous pulmonary nodules had mildly increased in size to 2 and 1.6 cm and a few small new nodules were present as well (Fig. 1b). Radiographs and ultrasound of the caudal abdomen revealed marked sublumbar lymphadenopathy and local invasion of the lumbar vertebrae. No other abdominal abnormalities were found (Fig. 2a and b). Radiographs of the distal long bones had a palisading periosteal reaction, with the typical appearance of HO (Fig. 3a and b). Due to the extension, the lack of control of the disease and the development of HO, the patient was euthanized.

Discussion

In many ways this case is typical of anal sac adenocarcinoma (ASAC), a tumour that classically metastasizes early in the course of the disease with 79% of cases having sublumbar metastases at time of presentation and frequently associated with paraneoplastic hypercalcaemia in 25-53% of cases (Ross *et al.*, 1991; Bennett *et al.*, 2002; Williams *et al.*, 2003). The unusual feature of this case is the development of HO, relatively late in the course of the disease, without a significant radiographically detectable progression of the existing pulmonary pathology. The pulmonary nodules were initially assumed to be metastases from the ASAC, as the dog had no history or evidence of concurrent malignant disease. The slow progression of the nodules were considered to be consistent with the documented behaviour of this ASAC (Jeffery *et al.*, 2000; Polton and Brearley, 2007) but a post mortem examination was not performed to confirm this to be the case.

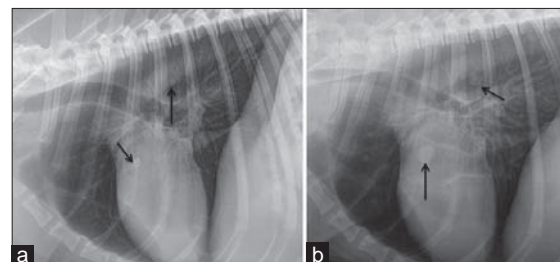


Fig. 1. Lateral chest radiographs. (a) Shows two small rounded soft tissue opacities in the lung fields (black arrows) at first presentation. (b) Shows a more diffuse nodular interstitial pattern, with nodules of different sizes consistent with metastases at third presentation. Increased in size of nodules seen in image a (black arrow).

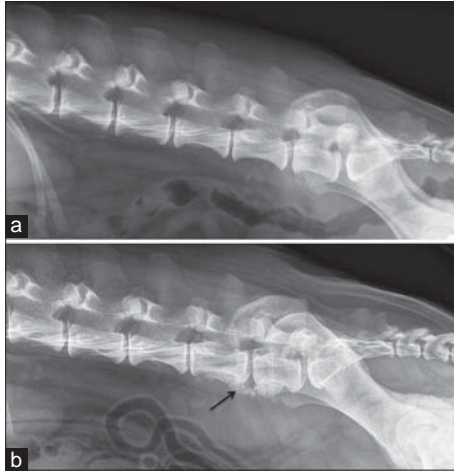


Fig. 2. Caudal abdominal radiographs at first (a) and 3rd examination (b). (a) Soft tissue opacity ventral to lumbar vertebrae 6 and 7 displacing the colon ventrally consistent with moderate sublumber lymph node enlargement. (b) Large multilobulated soft tissue opacity ventral to L6, L7, displacing the colon ventrally, and concurrent moth eaten lysis and new bone at L6 and L6-L7 (black arrow), consistent with lymph node and vertebral metastases.

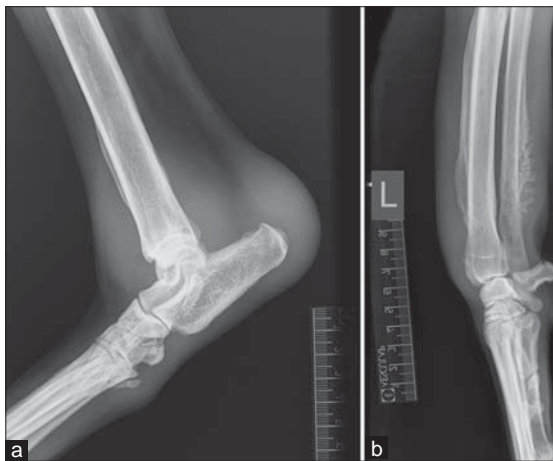

Fig. 3. (a) Medio-lateral view of the right hock shows marked soft tissue swelling, lamellar periosteal reaction on distal tibia, dorsal and plantar aspect of the tuber calcis and dorsally on the metatarsal bones. (b) Medio-lateral view of the left antebrachium shows marked soft tissue swelling, diffuse lamellar periosteal reaction on the cranial aspect of the radius and lamellar and palisading periosteal reaction on the distal ulna diaphysis.

The main challenge in the management of this case was the recurrence of the metastases in the sublumber lymph nodes with a concomitant hypercalcaemia. Control of the tumour and the nodal metastases resulted in normalization of the calcaemia. Oral bisphosphonate (clodronate) was preferred to injectable bisphosphonate in this case due to the good clinical condition of the dog and the resolution of the hypercalcaemia after tumour

control. Surgical resection is the treatment of choice for ASAC and as shown in this case, surgical resection of metastatic sublumber nodes is possible and can restore normocalcaemia. The value of adjunctive treatment is debatable with some patients achieving long term survival with only surgery (Hobson *et al.*, 2006). Post-operative RT may be used at primary site where completeness of excision is uncertain, although the proximity to anus can lead to potential complications. The value of chemotherapy in prevention and management of metastatic disease is less well defined, but treatment with both carboplatin and mitoxantrone have been reported (Polton and Brearley, 2007), as has melphalan (Emms, 2005). More recently, toceranib has been reported to achieve clinical benefit in 28/32 dogs with ASAC (London *et al.*, 2012).

HO has been described in numerous reports mainly associated with an extensive mass in the chest, or diffuse cancerous or non-cancerous pathology affecting the lungs; this is only the second report of HO in a dog with anal sac carcinoma (Hammond *et al.*, 2009).

This case is of interest due to the fact that the dog did not have extensive pulmonary pathology, or any respiratory signs. The two small nodules present on initial presentation did not cause initially any signs of HO and the few small new nodules visible on the last thoracic radiograph were considered unlikely to be the cause of the HO. The dog had also suffered from significant and recurrent sublumber lymphadenopathy, during the course of his treatment, so this also seems unlikely to be the cause or trigger of HO. No other abdominal lesions were noted on ultrasound examination. It has been reported that there is no consistent radiographical finding regarding location, number and size of the pulmonary nodules (Withers *et al.*, 2013). Therefore, it was reasonable to think that a mild increase in number and size of the nodules in the chest would not be, although possible, a reasonable explanation of the HO. It is interesting to note that the HO developed three months after toceranib was stopped. This drug is a selective inhibitor of VEGF and PDGF receptors. Recent publications have proposed a connection between increases these two growth factors in the periosteum and HO (Dickinson and Martin, 1987; Martinez-Lavin, 2007). The administration of toceranib could have bound the VEGF and PDGF receptors in this case, causing a delay in the appearance of the HO which only became evident after withdrawal of the drug.

In conclusion, this is the second reported case of metastatic apocrine gland carcinoma of the anal sac associated with HO and unusually describe the development of HO very late in the stage of the disease.

References

- Bennett, P.F., DeNicola, D.B., Bonney, P., Glickman, N.W. and Knapp, D.W. 2002. Canine

- anal sac adenocarcinomas: Clinical presentation and response to therapy. *J. Vet. Intern. Med.* 16, 100-104.
- Brodey, R. 1971. Hypertrophic osteoarthropathy in the dog: A clinicopathologic study of 60 cases. *J. Am. Vet. Med. Assoc.* 159, 1242.
- Carroll, K.B., and Doyle, L. 1974. A common factor in hypertrophic osteoarthropathy. *Thorax.* 29(2), 262-264.
- Dickinson, C.J. and Martin, J.F. 1987. Megakaryocytes and platelet clumps as the cause of finger clubbing. *Lancet.* 2, 1434-1435.
- Emms, S.G. 2005. Anal sac tumours of the dog and their response to cytoreductive surgery and chemotherapy. *Aust. Vet. J.* 83, 340-343.
- Halliwell, W.H. and Ackerman, N. 1974. Botryoid rhabdomyosarcoma of the urinary bladder and hyperosteoarthropathy in a young dog. *J. Am. Vet. Med. Assoc.* 165, 911-913.
- Hammond, T.N., Turek, M.M. and Regan, J. 2009. What is your diagnosis? Metastatic anal sac adenocarcinoma with paraneoplastic hypertrophic osteopathy. *J. Am. Vet. Med. Assoc.* 235(3), 267-268.
- Hesselink, J.W. and van den Tweel, J.G. 1990. Hypertrophic osteopathy in a dog with a chronic lung abscess. *J. Am. Vet. Med. Assoc.* 196, 760-762.
- Hobson, H.P., Brown, M.R. and Rogers, K.S. 2006. Surgery of Metastatic Anal Sac Adenocarcinoma in Five Dogs. *Vet. Surg.* 35, 267-270.
- Jeffery, N., Phillips, S.M. and Brearley, M.J. 2000. Surgical management of metastases from anal sac apocrine gland adenocarcinoma of dogs. *J. Small Anim. Pract.* 41, 390.
- Lee, J.H., Lee, J.H., Yoon, H.Y., Kim, N.H., Sur, J.H. and Jeong, S.W. 2012. Hypertrophic osteopathy associated with pulmonary adenosquamous carcinoma in a dog. *J. Vet. Med. Sci.* 74(5), 667-672.
- London, C., Mathie, T., Stingle, N., Clifford, C., Haney, S., Klein, M.K., Beaver, L., Vickery, K., Vail, D.M., Hershey, B., Ettinger, S., Vaughan, A., Alvarez, F., Hillman, L., Kiselow, M., Thamm, D., Higginbotham, M.L., Gauthier, M., Krick, E., Phillips, B., Ladue, T., Jones, P., Bryan, J., Gill, V., Novasad, A., Fulton, L., Carreras, J., McNeill, C., Henry, C. and Gillings, S. 2012. Preliminary evidence for biologic activity of toceranib phosphate (Palladia (®)) in solid tumours. *Vet. Comp. Oncol.* 10(3), 194-205.
- Makungu, M., Malago, J., Muhairwa, A.P., Mpanduji, D.G. and Mgasa, M.N. 2007. Hypertrophic osteopathy secondary to esophageal foreign body in a dog - a case report. *Vet. Arhiv.* 77, 463-467.
- Martinez-Lavin, M. 2007. Exploring the cause of the most ancient clinical sign of medicine: Finger clubbing. *Semin. Arthritis Rheum.* 36, 380-385.
- Mather, G. and Low, D. 1953. Chronic pulmonary osteoarthropathy in the dog. *J. Am. Vet. Med. Assoc.* 122, 167-171.
- Polton, G.A. and Brearley, M.J. 2007. Clinical stage, therapy, and prognosis in canine anal sac gland carcinoma. *J. Vet. Intern. Med.* 21(2), 274-280.
- Ross, J.T., Scavelli, T.D., Matthiesen, D.T. and Patnaik, A. 1991. Adenocarcinoma of the apocrine glands of the anal sac in dogs: A review of 32 cases. *J. Am. Anim. Hosp. Assoc.* 27, 349-355.
- Salyusarenko, M., Peeri, D., Bibring, U., Ranen, E., Bdolah-Abram, T., Aroch, I. 2013. Hypertrophic Osteopathy: A Retrospective Case Control Study of 30 Dogs. *Israel J. Vet. Med.* 68, 209-217.
- Watrous, B.J. and Blumenfeld, B. 2002. Congenital megaesophagus with hypertrophic osteopathy in a 6-year-old dog. *Vet. Radiol. Ultrasound* 43, 545-549.
- Williams, L.E., Gliatto, G.M., Dodge, R.K., Johnson, J.L., Gamblin, R.M., Thamm, D.H., Lana, S.E., Szymkowski, M. and Moore, A.S. 2003. Carcinoma of the apocrine glands of the anal sac in dogs: 113 cases (1985-1995). *J. Am. Vet. Med. Assoc.* 223(6), 825-831.
- Withers, S.S., Johnson, E.G., Culp, W.T., Rodriguez, C.O., Skorupski, K.A. and Rebhun, R.B. 2013. Paraneoplastic hypertrophic osteopathy in 30 dogs. *Vet. Comp. Oncol.* doi: 10.1111/vco.12026.
- Withrow, S.J. 2001. Perianal tumors. In: Withrow SJ, MacEwen EG, eds. *Small Animal Clinical Oncology*, 3rd ed. Philadelphia, PA: WB Saunders. pp: 346-353.
- Wylie, K.B., Lewis, D.D., Pechman, R.D., Cho, D.Y. and Roy, A. 1993. Hypertrophic osteopathy associated with *Mycobacterium fortuitum* pneumonia in a dog. *J. Am. Vet. Med. Assoc.* 202, 1986-1988.